

Kon, E, et al, Platelet-Rich Plasma: New Clinical Application – A Pilot Study for Treatment of Jumper’s Knee, *Injury*, 2009; 40:598-603

This prospective pilot study evaluated the efficacy of percutaneously injecting the growth factors found in platelet rich plasma (PRP) to treat chronic patellar tendinosis with a minimum of 6 month follow-up.

Methods


- Twenty (20) consecutive highly competitive (non professional) sports patients with Jumper’s Knee (characterized by microscopic ruptures with degenerative changes either in the distal quadriceps tendon or in the patellar tendon) were treated
 - All patients had a chronic condition, with a mean history of 20.7 months of pain.
 - All patients tried rest as a treatment and thirteen (13) non-operative techniques without success
 - Five (5) patients had undergone previous surgery
- The target area was identified by clinical landmarks and imaging evaluation with MRI or ultrasound, injections were performed without ultrasound guidance
- The injection technique involved 4-6 penetrations of the tendon using a 22-g needle, to distribute the PRP within and around the tendinous lesion
- Each case was clinically and functionally prospectively evaluated before treatment, after treatment, and at 6-month follow-up. Tegner, EQ VAS, and SF 36 questionnaires were used for clinical evaluation

Results

- The platelets were concentrated to a mean increase of 6 fold above baseline
- Approximately 6.8×10^6 platelets were delivered per injection
- At 6 months following percutaneous injection of PRP,
 - The PRP treated patients demonstrated statistically significant improvement in all scores (Tegner, EQ VAS, and SF 36) that were sustained over time
 - Functional evaluation showed six (6) completely recovered, eight (8) with marked improvement, two (2) with mild improvement, and four (4) no improvement
 - Three of four no improvement patients did not follow the post-injection stretching/strengthening program
 - Patient’s knee function and quality of life markedly improved
 - Patients returned to sport and previous activity levels in a median period of 2 months
 - There were no reported complications nor adverse events (e.g. effusion, infection, DVT, adhesion formation, and muscle atrophy)

Conclusions/Key Points

- Percutaneous injection of PRP in the degenerative area is a safe and effective method to reduce pain and improve tendon healing



Platelet-rich plasma: New clinical application A pilot study for treatment of jumper's knee

Elizaveta Kon^{a,*}, Giuseppe Filardo^a, Marco Delcogliano^a, Mirco Lo Presti^a, Alessandro Russo^a, Alice Bondi^a, Alessandro Di Martino^a, Annarita Cenacchi^b, Pier Maria Fornasari^b, Maurilio Marcacci^a

^a Biomechanics Laboratory, Department of Orthopaedic and Sports Trauma, Rizzoli Orthopaedic Institute, Via Di Barbiano 1/10, 40136 Bologna, Italy

^b Immunohaematology and Transfusion Medicine Service, Rizzoli Orthopaedic Institute, Via Di Barbiano 1/10, 40136 Bologna, Italy

ARTICLE INFO

Article history:

Accepted 14 November 2008

Keywords:

Platelet-rich plasma
Jumper's knee
Patellar tendinosis

ABSTRACT

This study describes a simple, low-cost, minimally invasive way to apply PRP growth factors to chronic patellar tendinosis; 20 male athletes with a mean history of 20.7 months of pain received treatment, and outcomes were prospectively evaluated at 6 months follow-up. No severe adverse events were observed, and statistically significant improvements in all scores were recorded. The results suggest that this method may be safely used for the treatment of jumper's knee, by aiding the regeneration of tissue which otherwise has low healing potential.

© 2008 Elsevier Ltd. All rights reserved.

Introduction

Jumper's knee is a troublesome condition of unknown aetiology and pathogenesis, characterised by microscopic ruptures with degenerative changes either in the distal quadriceps tendon or in the patellar tendon. The condition occurs most frequently in the origin of the patellar tendon origin on the inferior pole of the patella.⁶ It is a common and often chronic problem among athletes, and can severely limit or even end an athletic career.

This disorder affects athletes in many sports, particularly elite athletes engaged in high-impact jumping sports.¹² The prevalence of jumper's knee has been estimated to range between 40% and 50% among high-level volleyball players and between 35% and 40% among elite basketball players. There is also a high prevalence among soccer players, sprinters and jumpers.^{6,20}

Most athletes with this condition are young adults, who have to reduce their training and avoid certain activities, such as excessive jumping.⁷ An epidemiological evaluation showed that the average duration of pain and reduced function is nearly 3 years.¹⁹ A long-term prognostic study recorded that at 15 years follow-up 53% of those being followed reported having to quit their sports career because of their knee problem.¹⁸ Thus, it seems that jumper's knee commonly contributes to the decision to abandon an athletic

career, and causes mild but long-lasting symptoms that may remain after the athletic career is over.¹⁸

Most people with jumper's knee are treated non-operatively; several drugs and physical therapy methods are used to help the healing process. Initial treatments usually include rest, ice, electrotherapy, massage, anti-inflammatory medication or corticosteroid injections. However, there is no evidence-based support for the efficacy of these regimens.^{11,23} Recently, eccentric training has been proposed as effective treatment for patellar tendinosis^{24,31} but, in difficult cases where results are poor, surgical treatment may be considered and is recommended for athletes whose sports career seems to be in danger. Some studies report good surgical results,^{15,25} but the main treatment options are poorly researched, and outcomes after both operative and non-operative treatment may offer incomplete recovery and difficulties in returning to sport.^{1,8}

In recent years, several studies have described a complex regulation of growth factors for normal tissue structure and reaction to tissue damage, and have shown an important role for growth factor application in the healing of damaged tissue. Platelet-rich plasma (PRP) is a natural concentrate of autologous growth factors, which is now being widely tested in different fields of medicine for its possibilities in aiding the regeneration of tissue with low healing potential; fields of application include orthopaedics, sports medicine, dentistry, dermatology, ophthalmology and plastic, maxillofacial and cosmetic surgery. This method provides a simple, low-cost, minimally invasive way to apply many growth factors to the lesion site. To our knowledge, there are no

* Corresponding author. Tel.: +39 051 6366567; fax: +39 051 583789.
E-mail address: e.kon@biomec.ior.it (E. Kon).

studies on the clinical application of PRP via multiple injections to favour patellar tendon healing.

The aim of our study was to explore this novel approach to treating chronic patellar tendinosis, by gathering and assessing the number, timing, severity, duration and resolution of related adverse events occurring among study participants before and after treatment. The secondary aim was to analyse the results obtained, to determine feasibility, safety, indications and application of the method for further, wider studies.

Methods

Participant selection

Clinical experimentation was approved by the hospital ethics committee and informed consent of all participants was obtained.

The following diagnostic criteria for jumper's knee were used: history (>3 months) of exercise-associated pain, pain or tenderness on palpation, pain during provocative tests of the knee extensors, and findings of ultrasonography or magnetic resonance imaging showing degenerative changes of the tendons. Exclusion criteria included: systemic disorders such as diabetes, rheumatoid arthritis, haematological diseases (coagulopathies), severe cardiovascular disease, infections, immunodepression, therapy with anticoagulants, anti-aggregants or non-steroidal anti-inflammatory drugs in the 5 days before blood donation, haemoglobin values of <11 g/dl and platelets values of $<150 \times 10^9 \text{ l}^{-1}$.

For this study, 20 consecutive cases were treated and prospectively clinically evaluated at a minimum 6 months follow-up. Participants were all men, with a mean age of 25.5 years (range 18–47 years); 13 had a unilateral and 7 had bilateral lesions. The men practised sports at a highly competitive but not professional level in 16 cases, a high level in 2 cases and an amateur level in 2 cases. All had a chronic condition, with a mean history of 20.7 months pain (range 3–60 months), and had tried rest as treatment without any success. A total of 13 participants tried non-operative treatments (6 had received laser therapy, 6 ultrasound therapy, 9 shock wave therapy, 3 corticosteroid injection, 1 sclerosing therapy and 1 eccentric lengthening). Of these 13, 5 had undergone previous surgery (5 scarification, 1 coblation).

PRP preparation and injection

The procedure involved withdrawing a 150-ml venous blood sample (collected in 21 ml sodium citrate) for every lesion treated and for a complete peripheral blood count. Two centrifugations of 150 ml venous blood (the first at 1800 rpm for 15 min to separate erythrocytes, and the second at 3500 rpm for 10 min to concentrate platelets) produced a unit of 20 ml PRP. All the procedures were performed in the same office setting. The unit of PRP was divided into four smaller units of 5 ml each. All the open procedures were performed in an A-class sterile hood. One unit was sent to the laboratory for analysis of platelet concentration and quality test (platelet count and bacteriological test), one unit was used for the first injection within 2 h and the other two units were stored at -30°C . The total number of platelets/ml PRP represented a mean increase of 600% compared with whole blood values, and approximately 6.8 million platelets were applied to the lesion site at every injection.

Injections were administered every 15 days; for the second and third treatments, the samples were thawed in a dry thermostat at 37°C for 30 s just before application. Before the injection, 10% of CaCl_2 ($\text{Ca}^{2+} = 0.22 \text{ mequiv.} \times \text{dose}$) was added to the PRP unit to activate platelets. The skin was sterile dressed and the targeting area was identified by clinical landmarks and imaging evaluation with MRI or ultrasound images (the injections were performed

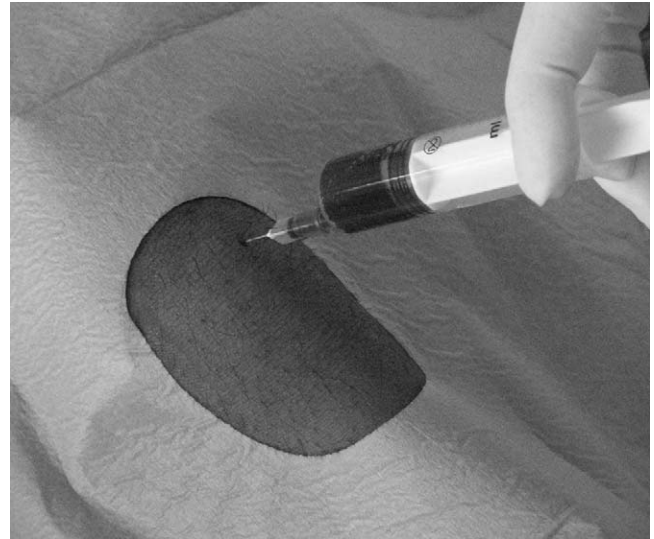


Fig. 1. Injection technique. Intratendinous and peritendinous PRP is distributed using a 22-g needle with a single or double skin portal and four to six penetrations of the tendon.

without ultrasound guidance). The injection technique involved a single or double skin portal and then multiple (four to six) penetrations of the tendon using a 22-g needle, to distribute the PRP within and around the tendinous lesion (Figs. 1 and 2). At the end of the procedure the participant remained supine for 15 min, to allow the PRP to remain localised.

Post-procedure protocol and follow-up evaluation

After the injection, the participants were sent home with instructions on limiting the use of the leg for at least 24 h and to

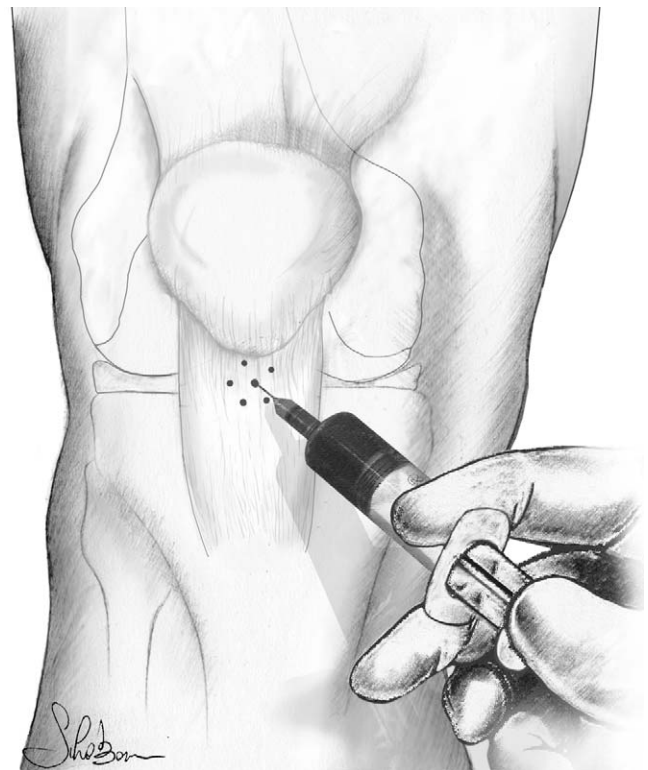


Fig. 2. Injection technique: schematic representation.

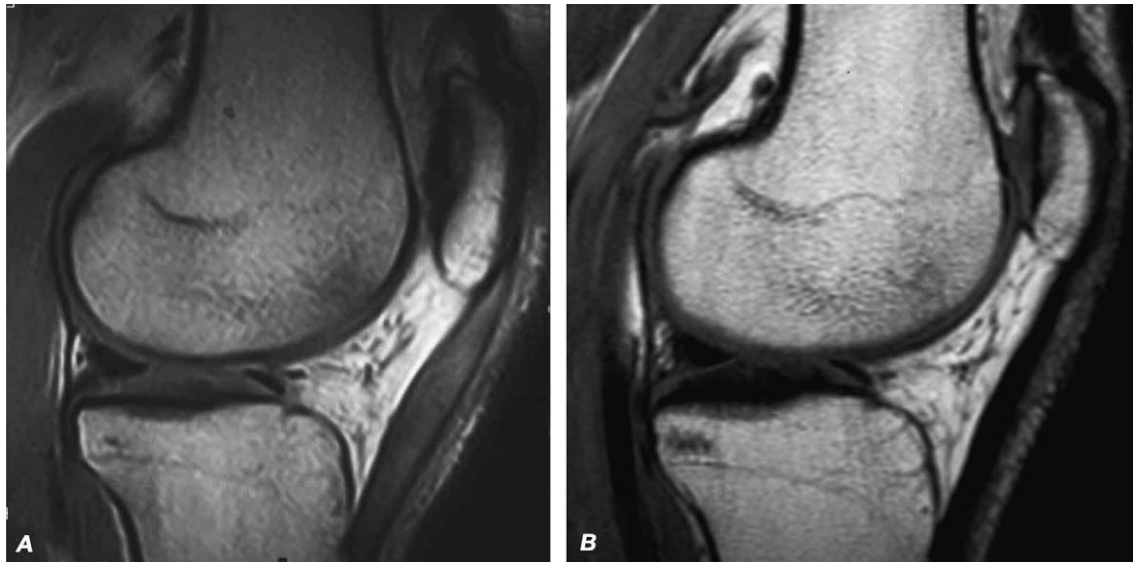


Fig. 3. Magnetic resonance imaging shows the patellar tendon (A) before the treatment and (B) at 6 months follow-up after PRP injections, demonstrating improved tendon structure.

use cold therapy/ice on the affected area for pain. During this period non-steroidal medication was allowed. Between the first and the second injection, rest was indicated. After the second injection, stretching exercises and mild activities (e.g. exercise bicycle or pool) were suggested. After the third application, participants were encouraged to continue with stretching and light activities, to begin a strengthening programme and to proceed gradually after 1 month with normal sport or recreational activities as tolerated.

Each case was clinically prospectively evaluated before and at the end of the treatment, and at 6 months follow-up. Tegner, EQ VAS and SF 36 questionnaires were used for clinical evaluation. Complications, functional recovery and participant satisfaction were also recorded.

Statistical method

Power analysis was performed: the goal of the study was to test the null hypothesis that the mean difference between basal and follow-up EQ VAS values was different from 0. The mean clinically significant difference was set at 15 points and the standard deviation at 20 points. The criterion for significance (α) was set at 0.05. With a sample size of 20 cases, the study had power of 88.9%.

All continuous data were expressed in terms of mean \pm standard deviation or median and range. The paired *t*-test (normally distributed data) or the Wilcoxon test (data not normally distributed) was used to analyse the difference between basal and follow-up values. The Mann–Whitney test evaluated by the Monte Carlo method for small samples was used to test the hypotheses regarding continuous data differences between groups. For all tests $p < 0.05$ was considered significant. Statistical analysis was performed using SPSS 15.0 for Windows (SPSS, Chicago, IL, USA) at Rizzoli Orthopaedic Institute.

Results

All results are presented as number of tendons treated (not number of individuals).

No complications related to the injections nor any severe adverse events were observed during the treatment or follow-up

Table 1

Pain and stiffness levels after the injections, recorded on 1–10 scale.

Symptom	Intensity		Duration (days)	
	Mean \pm S.D.	Range	Mean \pm S.D.	Range
Pain	6.1 \pm 1.4	2–9	1.5 \pm 0.7	1–3
Stiffness	6.2 \pm 1.9	1–8	2.2 \pm 1.1	1–4

S.D., standard deviation.

period. In only one case a marked pain response occurred after the injection and lasted 3 weeks. In all other cases, we recorded moderate pain and stiffness for a few days (Table 1).

A statistically significant improvement in all scores was observed after 6 months (Fig. 3). Statistical analysis showed a significant improvement in results of the SF36 questionnaire in all parameters evaluated at the end of the therapy and at 6 months follow-up (Table 2), and in the results of the EQ VAS (paired *t*-test, $p < 0.0005$) from basal evaluation to the end of the therapy and further at 6 months follow-up (paired *t*-test, $p = 0.011$) as shown in Fig. 4.

In each case the sports activity, which was evaluated using the Tegner score, showed a statistically significant improvement (Wilcoxon test, $p < 0.0005$) from pre-treatment level to 6 months follow-up; most of the men returned to practise their sport, with a lower score but not with a statistically significant difference compared with the previous activity level (Fig. 5).

The evaluation of functional recovery showed six men with complete recovery, eight with marked improvement, two with mild improvement and, in four cases, no improvement. Participant satisfaction, defined as satisfied or not satisfied with results of treatment, was 80% (16/20).

In order to establish the indications for this type of treatment, we tried to determine the parameters that influenced the clinical outcome. Participants who did not follow the post-procedure protocol achieved lower results in the Tegner score (3.2 ± 0.5 versus 7.7 ± 1.6 , Mann–Whitney test, $p < 0.0005$) and in the EQ VAS (59 ± 17 versus 85 ± 12 , Mann–Whitney test, $p = 0.005$). In three of the four failed cases, the men did not follow the stretching and strengthening programme. In the fourth, there was no improvement even after a protocol of eccentric lengthening in addition to

Table 2

SF 36 evaluation: scores show statistically significant improvement in all parameters at the end of therapy. The improvement is maintained or increased at 6 months follow-up (paired *t*-test).

Parameter	Before therapy	End of therapy	At 6 months follow-up	End versus start of therapy (<i>p</i> value)	6 months follow-up versus end of therapy (<i>p</i> value)
Physical function	56.7	82.0	86.7	<0.0005	0.272
Role limitations due to physical factors	13.9	43.5	87.0	0.002	<0.0005
Pain	35.7	63.8	71.6	<0.0005	0.205
General mental health	64.9	75.1	78.5	0.002	0.122
Vitality	59.1	68.9	68.7	<0.0005	0.921
Social functioning	49.1	69.9	84.3	<0.0005	0.004
Role limitations due to emotional factors	40.7	88.9	91.4	<0.0005	0.690
General health perceptions	69.1	78.1	85.9	0.003	0.001

treatments tried before the injection, such as shock wave, ultrasound and two operations; we did not record any progress with scarification and coblation. After 6 months the man was treated again and, during surgery, intratendinous calcifications were found and removed. In the other cases, where good results were obtained, return to sport and previous activity levels were achieved in a median period of 2 months (range 1–4 months) after the third injection (Fig. 6).

Discussion

Jumper's knee is one of the most common overuse injuries among both male and female athletes; it is an insertional tendinopathy that causes pain and subsequent dysfunction. Jumper's knee is not an inflammatory condition; it occurs because of the high chronic repetitive loading that exceeds the adaptive abilities of the tendon and causes microscopic tears and degeneration in the tendon substance. The poor regenerative ability of tendons, explained by the poor vascularity, oxygenation and nutrition of this tissue, cannot cope with the applied forces and chronic degenerative tendinopathy may develop.

Certain factors have been suspected of predisposing athletes to this condition.^{18,20} Anatomical, biomechanical and other intrinsic factors such as gender, age and overweight, and extrinsic factors, such as excessive loading, training errors and poor environmental conditions, play important roles in the development of this pathology by tending to increase the loading of the extensor apparatus and thus susceptibility to tendon disorders. Although cyclic loads may be well within the ultimate failure stress range of tendons, these can fatigue under high repetitive loading, as

confirmed by the fact that most people report a gradual onset of their symptoms.²⁹ Continued abusive load and irritation stimulate the local release of cytokines, with an autocrine and paracrine modulation of cell activity.¹⁴ When tissue breakdown exceeds repair and the cell matrix fails to adapt to the load, the tendinosis process is initiated with the formation of an initially asymptomatic focal area of intratendinous damage. The histological changes suggest that the pathological process is degenerative, without signs of inflammation.²⁰ Tendinosis is a collection of various histological entities, and the degenerative damage accumulates a long time before the first perception of symptoms such as pain, stiffness, tenderness or discomfort, as well as before any attempt at treatment. The slower and more insidious the onset of the injury and its symptoms, the slower and longer the recovery; this theoretical model of the pathophysiology of overuse injuries explains the difficulties in the treatment of chronic tendon disease.¹⁴

The most recent knowledge regarding tissue biology highlights a complex regulation of growth factors for normal tissue structure and reaction to tissue damage. Several studies have reported the important role of growth factors (GFs) in tendon regeneration and the effectiveness of growth factor application for healing damaged tissue. Studies have demonstrated the role of TGF- β ,^{16,17} which increases expression of procollagen types I and III and improves mechanical properties. PDGF-BB, IGF-1, VEGF and BFGF also promote tendon cell proliferation and tendon healing.^{9,22} It has been shown that healing tendon is responsive to the local application of growth factors, and the fact that platelets secrete growth factors and active metabolites means that they can have a

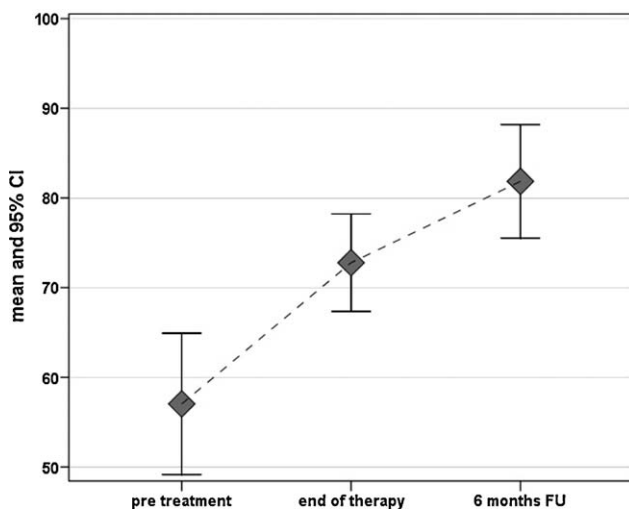


Fig. 4. Health status evaluated with EQ-VAS (means and CIs). CI, confidence interval; FU, follow-up.

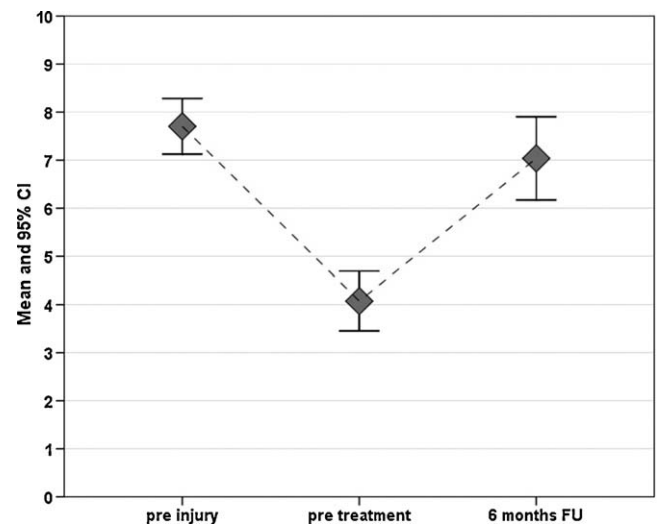


Fig. 5. Sport activity level evaluated with the Tegner score (means and CIs). CI, confidence interval; FU, follow-up.

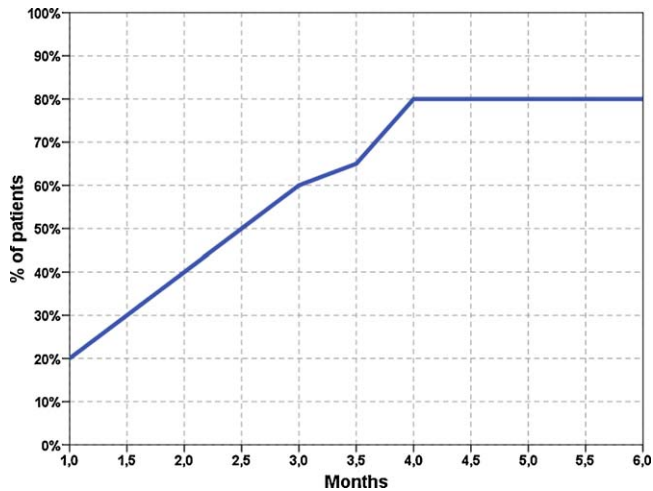


Fig. 6. Percentage of participants resuming sports after treatment, at different follow-up points.

positive influence on clinical situations requiring rapid healing and tendon regeneration. Recently, good clinical results have been reported in the treatment of chronic patellar tendinopathies with the use of autologous blood injections to provide mechanical and biological stimulation. The benefits documented are the result of some kind of bleeding, which stimulates the healing response through cellular and humoral mediators that induce the healing cascade, with the formation of granulation tissue and tissue regeneration favouring tendon repair.¹³

Platelets contain storage pools of growth factors including platelet-derived growth factor (PDGF), transforming growth factor (TGF- β), platelet-derived epidermal growth factor (PDEGF), vascular endothelial growth factor (VEGF), insulin-like growth factor 1 (IGF-1), fibroblastic growth factor (FGF), epidermal growth factor (EGF) and cytokines including proteins such as platelet factor 4 (PF4) and CD40L. Chemokines and newly synthesised metabolites are also released.²⁷ The growth factors are a diverse group of polypeptides that have important roles in the regulation of growth and development of a variety of tissues. Their administration in the form of platelet gel provides an adhesive support that can confine secretion to a chosen site. Additionally, the presentation of growth factors attached to platelets and fibrin may result in enhanced activity involving recombinant proteins.²

Releasate from PRP has been seen to stimulate gene expression of the matrix molecules,²⁸ collagen production¹⁰ and tendon cell proliferation in tendon culture. *In-vitro* studies^{3,4} have demonstrated the mitogenic activity, and also that stimulated tenocytes synthesise VEGF and HGF, suggesting a beneficial effect for the treatment of tendon injuries by inducing cell proliferation and promoting the synthesis of angiogenic factors during the healing process. Animal studies have confirmed the usefulness of platelet concentrate for the treatment of tendon damage,^{5,30} with an increased tendon callus strength and stiffness after percutaneous injections in transected tendons. In addition, a more rapid recovery in surgically repaired tendons treated with PRP has been recorded in a human study.²⁶

For the time being, the evidence base for PRP's clinical use is in its infancy, and there are only a few papers that specifically address treatment applications in the orthopaedic field. In particular, to our knowledge, there are no previously published studies regarding the PRP treatment of jumper's knee. However, the only study in humans on tendon treatment using multiple PRP injections for tennis elbow reports promising results.²¹

PRP has been a controversial treatment, because it was considered to resemble blood product manipulations that are

prohibited in sports. However, even if it derives from blood, it does not enhance sport performance. PRP is injected into the lesion and the gel maintains the growth factors in the lesion site, so that PRP cannot influence other tissues. Healing is assisted, but no athlete returns to play before at least 1 month after the last injection, when the lesion is healed and no growth factors are detectable in the repaired site, nor is PRP a prohibited method for the enhancement of the oxygen transfer, as the red blood cells (responsible for blood doping) are separated and eliminated through centrifugation before injection. The World Anti-Doping Agency is now studying the problem, but currently this procedure is not included in the WADA Prohibited List.

The aim of our study was to explore this novel approach for the treatment of chronic patellar tendinosis and to evaluate the safety of our protocol, by gathering and assessing the number, timing, severity, duration and resolution of related adverse events. No complications such as effusion, infection, marked muscle atrophy, deep vein thrombosis, fever, haematoma, tissue hypertrophy, adhesion formation or other major adverse events occurred among participants. The only minor adverse event detected was moderate pain and stiffness after the injections, which persisted for few days, except in 1 case which took 3 weeks to resolve. The secondary aim of the study was to evaluate the preliminary results obtained, in order to determine feasibility and potential of this new therapeutic approach, and to analyse indication criteria and application methods for further studies.

We observed a statistically significant improvement in all scores evaluated at the end of the therapy and at 6-month follow-up. Knee function and quality of life markedly improved, and the majority of the participants had a good recovery, returned to their previous sport activity level and were satisfied with the results of the treatment. Further evaluation of the correlation of the different variables showed that the post-procedure protocol markedly influenced the results: participants who did not follow the rehabilitation programme achieved poorer results. Stretching and strengthening therapies, which had failed before treatment, played a key role in rehabilitation after the PRP injections. This could be explained on one hand by the interplay between biological and mechanical stimulation increasing the healing potential, as shown in an animal model,³⁰ and on the other hand by improved functioning of the extensor apparatus, which could reduce the overload and thus aid healing of the tendon and maintenance of the results over time.

The weak points of this study are the lack of a control group and the low number of people treated; however, clear indications have emerged regarding safety, feasibility and potential of this treatment option.

This report outlines the first *in vivo* human investigation of the use of autologous growth factors to treat jumper's knee by means of PRP injections, and demonstrates that this is a safe method to improve tendon healing, with promising results. Further double-blind trials are needed in the future to confirm the results obtained, and a report on cost-effectiveness would also be useful before wide clinical application.

Conclusions

The clinical results of our pilot study are encouraging and suggest that this method may be used for the treatment of jumper's knee. The preliminary short-term results indicate that treatment with PRP injections in the degenerate area has the potential to reduce pain and allow the majority of patients to go back to full tendon-loading activity. However, long-term randomised controlled studies will be needed to confirm the reliability of this procedure, identify indication criteria and improve application

methods; further studies evaluating this new technique for treating jumper's knee are in progress.

Acknowledgments

We thank the following for their assistance: S. Zaffagnini, S. Bassini, F. Pieretti, A. Gabriele, M. Vaccari, A.M. Del Vento, M. Zagarella, V. Roverini, I. Brognara, L. D'Amato, S. Ardone, Elettra Pignotti, Keith Smith.

References

- Almekinders L, Temple J. Etiology, diagnosis and treatment of tendonitis: an analysis of the literature. *Med Sci Sports Exerc* 1998;30:1183–90.
- Anitua E, Andia I, Ardanza B, et al. Autologous platelets as a source of proteins for healing and tissue regeneration. *Thromb Haemost* 2004;91:4–15.
- Anitua E, Andia I, Sanchez M, et al. Autologous preparations rich in growth factors promote proliferation and induce VEGF and HGF production by human tendon cells in culture. *J Orthop Res* 2005;23:281–6.
- Anitua E, Sanchez M, Nurdan AT, et al. Autologous fibrin matrices: a potential source of biological mediators that modulate tendon cell activities. *J Biomed Mater Res A* 2006;77:285–93.
- Aspenberg P, Virchenko O. Platelet concentrate injection improves Achilles tendon repair in rats. *Acta Orthop Scand* 2004;75:93–9.
- Bahr R, Fossan B, Loken S, et al. Surgical treatment compared with eccentric training for patellar tendinopathy (jumper's knee). A randomized, controlled trial. *J Bone Joint Surg Am* 2006;88:1689–98.
- Cook JL, Khan KM, Harcourt PR, et al. A cross sectional study of 100 athletes with jumper's knee managed conservatively and surgically. *Br J Sports Med* 1997;31:332–6.
- Cook JL, Kiss ZS, Khan KM, et al. Anthropometry, physical performance, and ultrasound patellar tendon abnormality in elite junior basketball players: a cross sectional study. *Br J Sports Med* 2004;38:206–9.
- Costa MA, Wu C, Pham BV, et al. Tissue engineering of flexor tendons: optimization of tenocyte proliferation using growth factor supplementation. *Tissue Eng* 2006;12:1937–43.
- De Mos M, Van der Windt AE, Jahr H, et al. Can platelet-rich plasma enhance tendon repair? A cell culture study. *Am J Sports Med* 2008;36:1171–8.
- Fredberg U, Bolvig L. Jumper's knee. Review of the literature. *Scand J Med Sci Sports* 1999;9:66–73.
- Gisslen K, Alfredson H. Neovascularisation and pain in jumper's knee: a prospective clinical and sonographic study in elite junior volleyball players. *Br J Sports Med* 2005;39:423–8.
- James SL, Ali K, Pocock C, et al. Ultrasound guided dry needling and autologous blood injection for patellar tendinosis. *Br J Sports Med* 2007;41:518–21.
- Josza LG, Kannus P. *Human Tendons. Anatomy, Physiology, and Pathology*. Champaign, IL, USA: Human Kinetics Books; 1997. pp. 178–84.
- Karlsson J, Lundin O, Lossing IW, et al. Partial rupture of the patellar ligament. Results after operative treatment. *Am J Sports Med* 1991;19:403–8.
- Kashiwagi K, Mochizuki Y, Yasunaga Y, et al. Effects of transforming growth factor-beta 1 on the early stages of healing of the Achilles tendon in a rat model. *Scand J Plast Reconstr Surg Hand Surg* 2004;38:193–7.
- Katsura T, Tohyama H, Kondo E, et al. Effects of administration of transforming growth factor (TGF)-beta1 and anti-TGF-beta1 antibody on the mechanical properties of the stress-shielded patellar tendon. *J Biomech* 2006;39:2566–72.
- Kettunen JA, Kvist M, Alanen E, et al. Long term prognosis for jumper's knee in male athletes: a prospective follow-up study. *Am J Sports Med* 2002;30:689–92.
- Lian OB, Engebretsen L, Bahr R. Prevalence of jumper's knee among elite athletes from different sports: a cross-sectional study. *Am J Sports Med* 2005;33:561–7.
- Lian O, Refsnes PE, Engebretsen L, et al. Performance characteristics of volleyball players with patellar tendinopathy. *Am J Sports Med* 2003;31:408–13.
- Mishra A, Pavelko T. Treatment of chronic elbow tendinosis with buffered platelet-rich plasma. *Am J Sports Med* 2006;34:1774–8.
- Molloy T, Wang Y, Murrell G. The roles of growth factors in tendon and ligament healing. *Sports Med* 2003;33:381–94.
- Peers KH, Lysens RJ. Patellar tendinopathy in athletes: current diagnostic and therapeutic recommendations. *Sports Med* 2005;35:71–87.
- Purdam CR, Jonsson P, Alfredson H, et al. A pilot study of the eccentric decline squat in the management of painful chronic patellar tendinopathy. *Br J Sports Med* 2004;38:395–7.
- Raatikainen T, Karpakka J, Puranen J, et al. Operative treatment of partial rupture of the patellar ligament. A study of 138 cases. *Int J Sports Med* 1994;15:46–9.
- Sanchez M, Anitua E, Azofra J, et al. Comparison of surgically repaired Achilles tendon tears using platelet-rich fibrin matrices. *Am J Sports Med* 2007;35:245–51.
- Sanchez A, Sheridan P, Kupp L. Is platelet-rich plasma the perfect enhancement factor? A current review. *Int J Oral Maxillofac Implants* 2003;18:93–103.
- Schnabel LV, Mohammed HO, Miller BJ, et al. Platelet rich plasma (PRP) enhances anabolic gene expression patterns in flexor digitorum superficialis tendons. *J Orthop Res* 2007;25:230–40.
- Stanish WD, Curwin S, Rubinovich M. Tendinitis: the analysis and treatment for running. *Clin Sports Med* 1985;4:593–609.
- Virchenko O, Aspenberg P. How can one platelet injection after tendon injury lead to a stronger tendon after 4 weeks? Interplay between early regeneration and mechanical stimulation. *Acta Orthop* 2006;77:806–12.
- Young MA, Cook JL, Purdam CR, et al. Eccentric decline squat protocol offers superior results at 12 months compared with traditional eccentric protocol for patellar tendinopathy in volleyball players. *Br J Sports Med* 2005;39:102–5.